

Successful Healing of IAD when Traditional Barriers Fail Using an Innovative Topical Formulation

Diana Lynn Gallagher MS, RN, CWOCN, CFCN
Janalynn Miller FNP-C, GNP, CWCN-AP

Problem

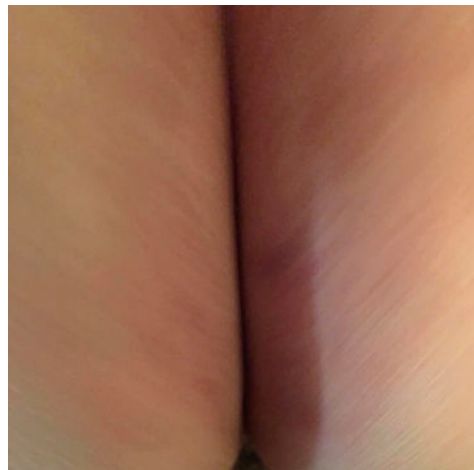
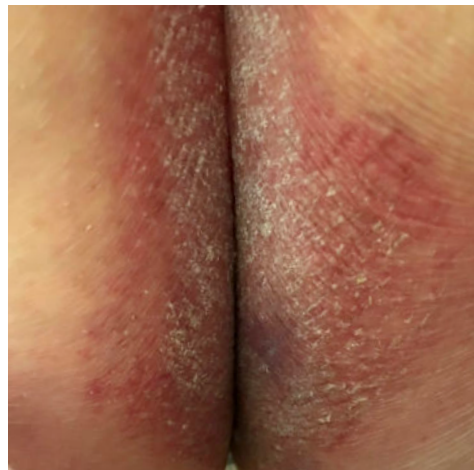
Incontinence Associated Dermatitis (IAD) is the result of urine and/or feces damaging skin. IAD results in over-hydration, edema, and breakdown of the Stratum Corneum. This damage increases skin's susceptibility to friction, elevates pH, and escalates erythema and erosion. In spite of traditional management programs including gentle cleansing and protection with various barriers, IAD remains a major problem that can persist indefinitely. Affected individuals experience discomfort and increased risk for complications (secondary infections and pressure injuries). With effective management, visible improvement is expected in 1-2 days with complete resolution in 1-2 weeks. Patients with IAD deserve a better approach than traditional management.

Research

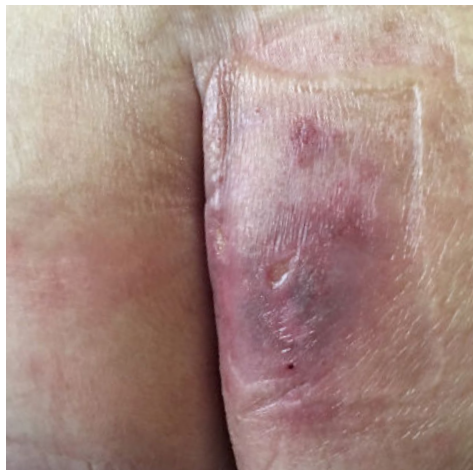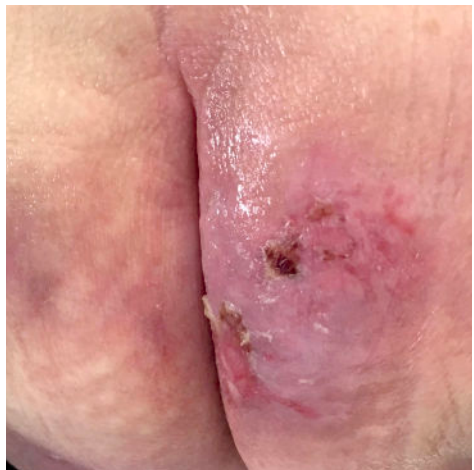
Twenty residents with IAD unresolved with traditional barriers were recruited from 7 post-acute care facilities across two states. Two had fecal incontinence, four had urinary incontinence and the remainder had mixed incontinence. Education and data collection tools were provided to guide the process. Staff assessed affected skin daily using a 3 point IAD differentiation scale (0 for normal skin, 1 for erythema, and 2 for open lesions). The two week treatment plan included discontinuation of other barrier products, gentle cleansing after incontinence followed by the application of a continuous topical barrier spray at least 4 times/24 hours. The spray optimizes skin quality and an acidic pH.

Results

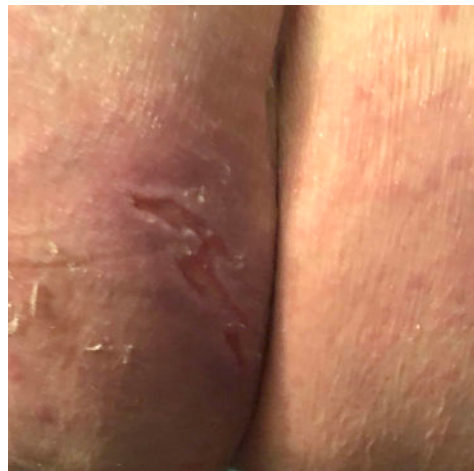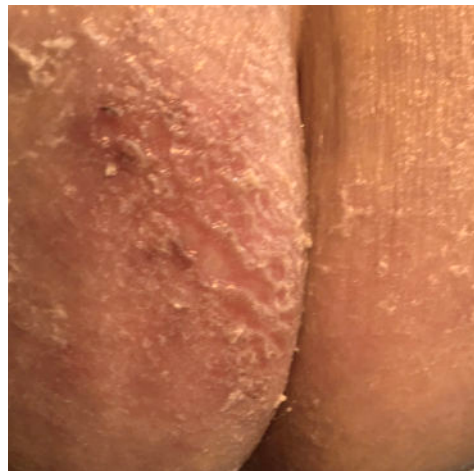In spite of education aimed at both nursing and nursing assistants and simple data collection tools, strict adherence to the plan was a significant challenge. In spite of compliance issues, results showed a significant improvement over traditional barrier products. Further research is needed, but this preliminary study holds promise for a paradigm shift and improved, cost-effective health outcomes.



Before ————— **After**



Before ————— **After**



Before ————— **After**

Fecal Incontinence	Mixed Incontinence	Urinary Incontinence
100% Resolution	93% Resolution	50% Resolution*

*A family switched back to traditional barriers, in spite of open lesions healing completely.

References

Beeckman D et al. Proceedings of the Global IAD Expert Panel. Incontinence-associated dermatitis: moving prevention forward. *Wounds International* 2015.

Langemo D, Hanson D, Hunter S, et al. Incontinence and Incontinence Associated Dermatitis. *Adv Skin Wound Care* 2011 24(3): 126-140

Incontinence Associated Dermatitis (IAD): Best Practice for Clinicians. WOCN 2014

Long M, Reed L, Dunning K, Ying J. Incontinence-associated dermatitis in a long term acute care facility. *JWOCN* 2012; 39(3):318-27